



The AMSA injection: A new concept for local anesthesia of maxillary teeth using a computer-controlled injection system

Mark J. Friedman, DDS*/Mark N. Hochman, DDS**

This article describes a new injection technique for the maxillary arch that achieves pulpal anesthesia of the central incisor through the second premolar without collateral anesthesia of the face and muscles of expression. This palatal injection can be delivered easily, consistently, and virtually imperceptibly with a recently introduced computer-controlled local anesthesia delivery system. The anterior (AMSA) middle superior alveolar block, is a single-site injection requiring less than one cartridge of anesthetic and is ideal for maxillary esthetic restorative dentistry because it does not distort the smile line. A clinical example is also presented.
(Quintessence Int 1998;29:297-303)

Key words: anterior and middle superior alveolar neurovascular bundles, maxillary local anesthesia

Clinical relevance

The described anesthesia system provides dentists with a contemporary alternative to the traditional local anesthetic syringe and represents a practical and efficacious concept for local anesthesia of maxillary teeth.

Dentists have traditionally anesthetized teeth in the maxillary arch with a supraperiosteal injection in the mucobuccal fold in proximity to the apices of the teeth to be anesthetized.¹ A recently introduced computer-controlled local anesthesia delivery system permits achievement of predictable and profound pulpal

anesthesia of multiple maxillary teeth from a single injection, using a minimal dosage of anesthetic and with no collateral anesthesia of overlying facial structures. This paper describes the clinical technique for anesthetizing the anterior and middle superior alveolar (AMSA) neurovascular bundles from a single, virtually imperceptible palatal injection via this computer-controlled device.² This new and highly predictable block injection simplifies anesthesia of maxillary teeth and has a significant positive impact on clinical procedures and patient comfort.³

History

A supraperiosteal injection in the mucobuccal fold is the most commonly utilized route of administration to achieve local anesthesia of maxillary teeth.⁴ This injection is referred to as an infiltration or field block and was first described by William Halsted in the late 1800s.⁵ It is a convenient, safe, and effective means of pain control for a variety of procedures performed on maxillary teeth and associated soft and hard tissues of the region.⁶ Anesthetic solution diffuses from the injection site, penetrating through the soft tissues, periosteum, and porous maxillary bone, and resulting in anesthesia of the radicular nerve fibers of the teeth in proximity to the injection site.⁷

*Clinical Professor of Restorative Dentistry, University of Southern California School of Dentistry, Los Angeles, California; Clinical Director, Milestone Scientific, Livingston, New Jersey.

**Clinical Assistant Professor, Department of Postgraduate Periodontics, State University of New York at Stony Brook, School of Dental Medicine; Associate Clinical Director, Milestone Scientific, Livingston, New Jersey.

Reprint requests: Dr Mark J. Friedman, Center for Dental Aesthetics, 16830 Ventura Blvd, Suite 258, Encino, California 91436. E-mail: mfriedma@hsc.usc.edu

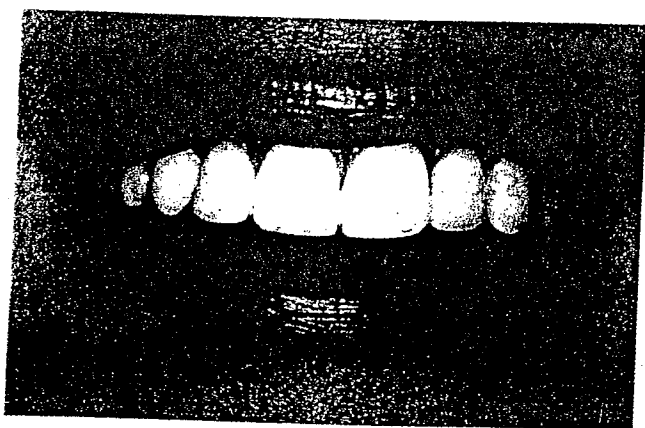


Fig 1a A 27-year-old patient with lips in repose to allow for accurate esthetic assessment of the six porcelain veneer restorations that have been placed on the maxillary anterior teeth.

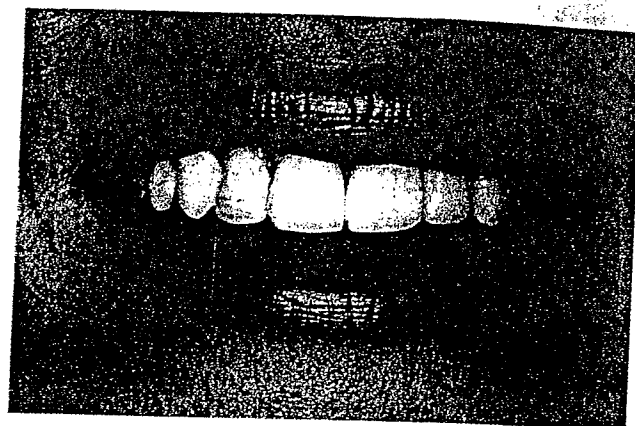


Fig 1b Same patient after a traditional infiltration of 0.6 mL of lidocaine with 1:100,000 epinephrine in the mucobuccal fold adjacent to the left lateral incisor demonstrates temporary lip distortion.

Multiple factors play a role in whether adequate pulpal anesthesia is achieved from a maxillary infiltration. They include density and thickness of the bone in the area, access to the anatomy, length of the tooth root(s) to be anesthetized, type and dosage of the anesthetic employed, and the patient's subjective pain threshold and response to painful stimuli.^{8,9} Since it is not uncommon for variations in anatomy to reduce the success of an infiltration, multiple needle penetrations may be necessary to ensure that an adequate volume of anesthetic solution is deposited to achieve the desired level of pain control for the targeted teeth.⁹ It is reasonable to predict that a maxillary field block, or infiltration, anterior to the first molar will result in concomitant anesthesia of the lip, surface of the face, and muscles of expression.¹⁰ The degree of collateral anesthesia often observed suggests that a significant portion of the anesthetic bolus, which is intended for the neurovascular bundles of the teeth at the site of the injection, dissipates into the overlying soft tissues.¹¹ Thus, only a portion of the anesthetic volume administered actually reaches the intended target site. The remaining superfluous solution affects tissues that ideally should remain unanesthetized.

Maxillary teeth can also be anesthetized with a variety of block injections (eg, infraorbital, posterior-superior alveolar, second division, etc), as well as intraligamentary (PDL) or intraosseous injections.¹² However, the literature does not describe a single injection site that would produce pulpal anesthesia to a majority of the maxillary teeth and do so without collateral anesthesia of the face, lip, and muscles of expression.

Site-specific anesthesia

A site-specific injection that would accurately target the neurovascular bundles, associated with the teeth, while

minimizing any effect to overlying soft tissues, would positively impact clinical techniques and patient comfort. In the anterior region of the maxilla, esthetic parameters are often of critical concern. Lip-to-teeth relationship assessments, considered vital to the quality of the finished results, cannot be adequately performed if the lip or muscles of expression are inadvertently anesthetized¹³ (Figs 1a and 1b). Therefore, a site-specific maxillary injection would greatly enhance the operator's ability to make accurate esthetic assessments while at the same time providing an adequate level of pain control. The patient would not experience the annoying sensation of facial numbness and the accompanying loss of muscle control associated with traditional non-site-specific injection techniques. Furthermore, if the majority of the administered anesthetic solution specifically targeted the teeth and adjacent gingival tissues, anesthetic dosages might be reduced without sacrificing the efficacy and duration of the dental anesthesia.

The ideal maxillary injection would produce a rapid onset of profound pulpal anesthesia for multiple teeth from a single needle penetration. It would not produce unnecessary collateral anesthesia, and it would only require a minimum dosage of anesthetic solution to be effective. It would be easy to administer without risk to any vital structures and would be virtually imperceptible during administration, making it of immense benefit to both the patient and the dentist.

A computer-controlled injection system

The Wand Local Anesthesia System (Milestone Scientific) is a computer-controlled injection device the size of a paperback book. It accommodates a conventional local anesthetic cartridge that is linked by microtubing to a disposable, lightweight, penlike handle with

a Luer lock needle attached (Fig 2). The computer-controlled system is activated by a foot control that automates the delivery of local anesthetic at precise pressure and volume ratios, resulting in an effective and comfortable injection. This eliminates the variability of the thumb-operated plunger used in a manual syringe.

The automation provided by computer control sustains a constant pressure and volume ratio of anesthetic fluid regardless of variations in tissue resistance. Thus, if the anesthetic solution is deposited into a tissue of resilience such as the palate, the computer drive compensates to ensure a steady and continuous rate of flow. Conversely, if the encountered resistance is reduced, plunger pressure is automatically adjusted.

Patients who have experienced an injection with this system report a virtually imperceptible needle penetration followed by a sensation of mild pressure.² The manufacturer suggests that needle penetration and advancement be done very slowly to allow for anesthetic to precede the path of the needle. One can speculate that maintaining an anesthetic pathway and an ideal rate of flow are the major factors responsible for achieving comfortable injections with the system.¹⁴

The AMSA nerve block

The fact that pulpal anesthesia can be accomplished from a palatal injection is well documented.^{1,15} During prototype development of the Wand Local Anesthesia System, an anecdotal finding (R. Spinello, York, PA) suggested that comfortable palatal pulpal anesthesia was feasible. Clinical investigation determined that the administration of 0.6 to 0.9 mL of local anesthetic, deposited at a specific single palatal site, produces profound pulpal anesthesia of the AMSA neurovascular bundles² (Fig 3). In addition, the palatal soft tissues of the region are anesthetized. Because of the palatal approach, this injection does not affect sensory fibers to the lip and face or alter the activity of the muscles of facial expression. Within 2 minutes of administration of this block injection, pulpal anesthesia extending from the central incisor to the second premolar is achieved. The palatal tissues extending from the midpalate to the free gingiva and from the central incisor to the first molar are also profoundly anesthetized from the injection. The duration of anesthesia is reported to be from 45 to 90 minutes. Hemostasis is also achieved in the same region, and some crossover hemostasis and anesthesia effect has been observed on the buccal aspect of the aforementioned teeth. This observation may be due, in part, to the efficient suffusion of anesthetic into the medullary bone that the controlled flow rate creates. A sufficient concentration of anesthetic solution deposited




Fig 2 The Wand computer-controlled local anesthetic delivery system consists of a microprocessor/drive unit, foot control, and lightweight plastic disposable handpiece.

in proximity to the major neurovascular bundles of the anterior and middle superior alveolar plexus might account for the marked hemostasis and profound anesthesia that can be developed from just 0.6 mL of lidocaine with 1:100,000 concentration of vasopressor injected into a single location.

It is speculated that due to the resilience of the palatal tissues, the majority of the anesthetic solution that is injected under precisely controlled pressure and flow rate reaches the underlying bone and neurovascular anatomy instead of being dissipated into the surrounding soft tissues. Based on clinical observations, it is conjectured that this injection is intraosseous in nature.

Traditionally, injections in the palate have been associated with a significant degree of discomfort.¹⁶ The literature is replete with articles describing ways to minimize the discomfort associated with palatal injections.¹⁷⁻²¹ The ability of the computer-assisted device to deliver anesthetic at a high pressure, but a slow rate of volume flow, is the core technology of the system. The primary explanation for the lack of discomfort reported with these injections is the separation of anesthetic flow rate from pressure.¹⁴ With a manual syringe, these pressure and volume parameters cannot be precisely controlled and they are directly linked.²² In manual delivery, an increase in pressure is automatically accompanied with an increase in volume. Any distention of palatal tissues results in significant discomfort for the patient. If the operator attempts to slowly inject the required 0.6 to 0.9 mL of anesthetic solution manually to achieve an AMSA block, muscle fatigue and physical limits make the procedure difficult. In addition, the precise pressure gradient that must be achieved and maintained for anesthetic to efficiently suffuse into the deeper anatomic structures without eliciting pain cannot

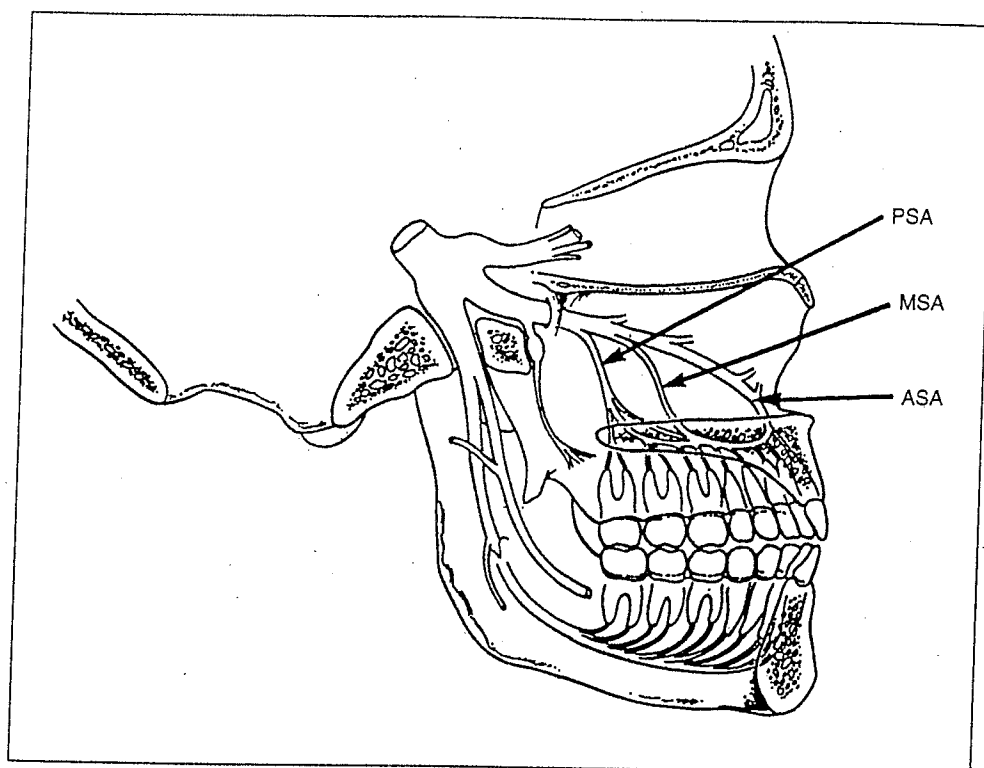


Fig 3 Sagittal section diagram depicting the distribution of the superior alveolar nerve. ASA = anterior superior alveolar nerve; MSA = middle superior alveolar nerve; PSA = posterior superior alveolar nerve.

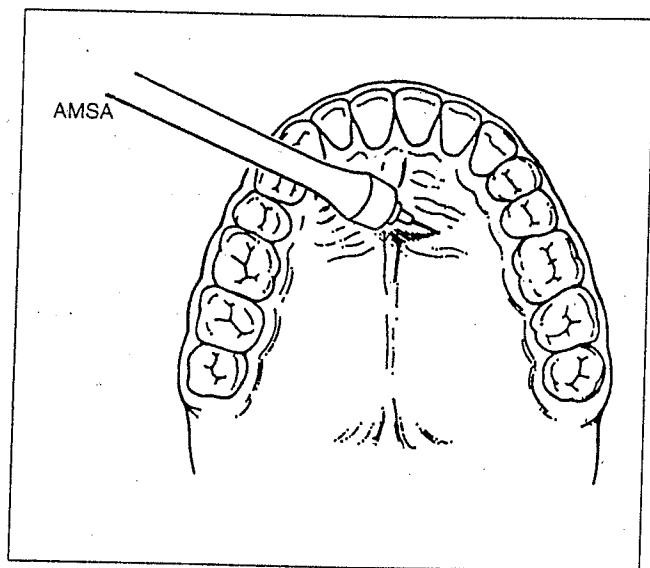


Fig 4 Palatal diagram depicting the injection site for the AMSA block injection. This site is considered to be approximately 1 cm in diameter and, therefore, not an exact point but rather a zone.

Figures 2, 3, 4, 5, 6, 8a, 8b, and 8c are reprinted with permission from *The Compendium of Continuing Education in Dentistry*. Friedman MJ, Hochman MN: A 21st century computerized injection system for local pain control. *Compend Contin Educ Dent* 18(10): 995-1004, 1997.

be reproduced manually. A recently published clinical study evaluating the subjective pain response from a computer-assisted palatal injection with a controlled flow rate demonstrated that 48 of 50 dentists reported this injection caused minimal or no pain.¹⁴

The AMSA injection site is located at a point that bisects the maxillary first and second premolars and is midway between the crest of the free gingival margin and the midpalatine suture (Fig 4). The use of a 30-gauge extra-short needle is ideal for the administration of the AMSA block. Topical anesthetic can be applied to the injection site. However, patients report that even in the absence of topical anesthetic, the injection experience is virtually imperceptible.

The needle is oriented at a 45-degree angle with the bevel facing the palatal tissue, as indicated in a traditional palatal injection technique.²³ As the bevel contacts the tissue, the foot switch is activated on the slow-rate position to ensure a positive flow of anesthetic at the moment of needle penetration (Figs 5 and 6). Because the anesthetic flow rate is precisely controlled automatically, the operator need only concentrate on the accurate and delicate placement of the needle, which is greatly enhanced by a pen grasp of the ultra-light handpiece.

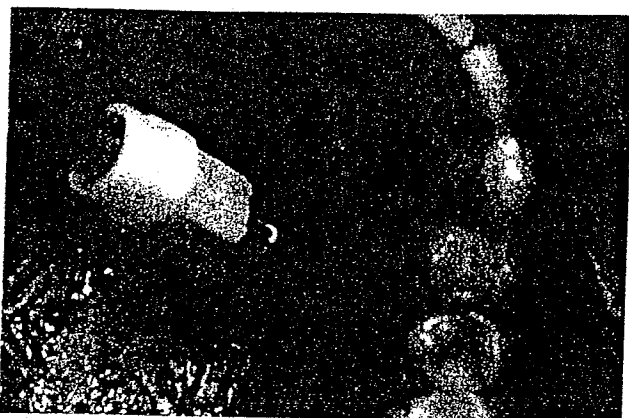

Fig 5 Palatal view of a 30-gauge extra-short needle in position for palatal AMSA penetration with anesthetic flow rate initiated. No topical anesthetic was employed.

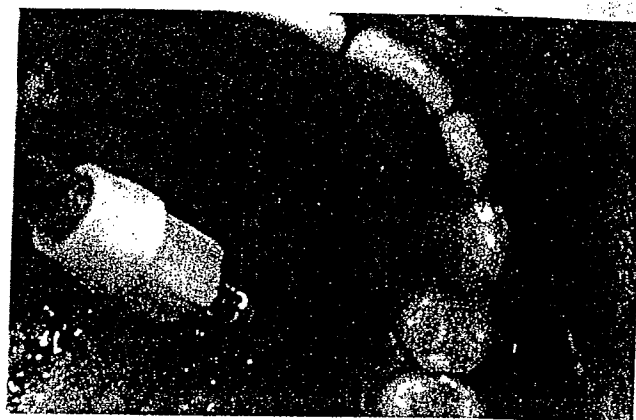

Fig 6 Needle is advanced as slowly as possible to ensure the creation of an anesthetic pathway.

Patients who have experienced an AMSA injection describe a slight sensation upon needle penetration and thereafter a mild feeling of pressure that is not unpleasant. Seconds after needle penetration, a definite blanching of the soft tissue surrounding the injection site is observed, indicating that the anesthetic is actively suffusing through the connective tissues, periosteum, and cancellous bone. The foot control has a low- and a high-rate position; in tissues of resistance such as the palate, the injection rate is maintained on the low position. Approximately 60 to 90 seconds may be required to administer the 0.6 to 0.9 mL of anesthetic solution necessary to achieve intrapulpal anesthesia of the central incisor through the second premolar for approximately 45 to 90 minutes. Additional anesthesia can be easily titrated in the area as required.

It is imperative that the operator visually monitor the level of tissue blanching. If excessive blanching occurs, indicated by a loss of all pink color to the tissues, a momentary pause is indicated to allow the anesthetic to dissipate and blood supply to return (Fig 7). In the unlikely event that marked ischemia develops, an ulcerative lesion may result within 24 to 48 hours of the injection. The lesion will resolve itself in 7 to 14 days.

Clinical example

A 46-year-old female patient sought elective esthetic restorative dentistry for correction of multiple, interproximal, discolored composite restorations on the maxillary anterior teeth. In addition, she wished to have the shade of her teeth lightened. The treatment plan was to restore the six maxillary anterior teeth with porcelain veneers to mask existing composite restorations and

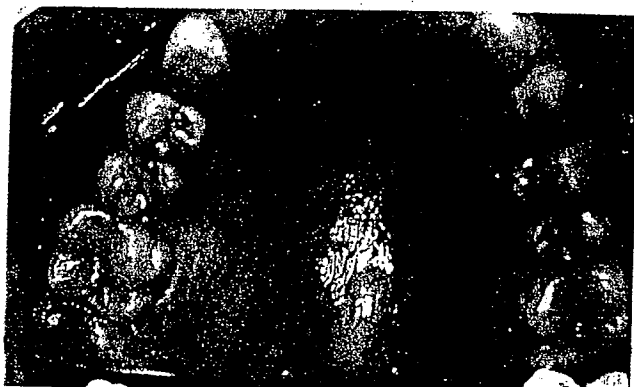

Fig 7 View of the palate of a 35-year-old patient 2 minutes after bilateral AMSA blocks were administered. Note the significant palatal blanching.

increase the value to approximately a Vita A-1 shade (Fig 8a). The patient was an interior designer by profession and reported having a discriminating perception relative to color and shape. Pretreatment discussions took place to review the importance of proper alignment and shape of the final restorations with the natural lip line. The patient agreed that this was a critical element to the final outcome and expressed a strong desire that every effort be made to achieve an ideal result.

At the initial operative appointment the patient was anesthetized with bilateral AMSA injections. Each injection was delivered with The Wand Local Anesthesia System utilizing a 30-gauge extra-short needle. At each injection site 0.9 mL of lidocaine with 1:100,000 epinephrine was administered without the use of topical anesthetic. The patient reported that the insertion of the needle was barely perceptible and was fol-

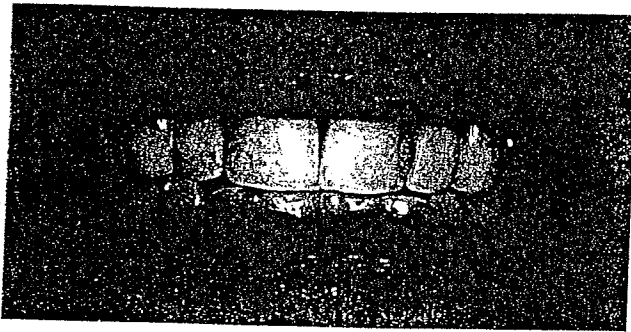


Fig 8a Preoperative conditions of a 46-year-old woman with multiple interproximal resin composite restorations. The treatment plan called for her to receive six porcelain veneer restorations.




Fig 8b The patient received bilateral AMSA block injections. In spite of complete pulpal anesthesia, the lips and muscles of expression remain unaffected and undistorted.

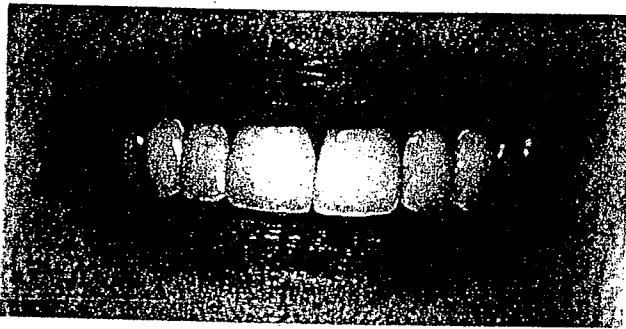


Fig 8c Immediately after the cementation of the porcelain veneer restorations, the patient is able to place lipstick and smile normally even though the teeth are completely anesthetized.

lowed by a mild sensation of pressure. Each injection required approximately 90 seconds to administer. Within 2 minutes the teeth were presumed to be fully anesthetized, as evidenced by the significant palatal blanching extending from the central incisor to the second premolar. Routine porcelain veneer preparations were performed with a fine No. 62 diamond (Lasco Products) and high-speed turbine (KaVo) without complication. During the 20 minutes required to prepare the six anterior teeth, the patient did not exhibit any behavior suggesting that she experienced any unpleasant sensations, and no additional anesthetic was required. The outline form and incisal reduction of the completed preparations was referenced to the lips in repose to ensure that adequate tooth structure had been removed (Fig 8b). The master impression was made with

Impregum Pentamix impression material (ESPE). The patient was instructed to wear a maxillary bleach splint as a provisional restoration and was dismissed. The patient was contacted on the evening of the appointment and reported that the anesthesia had dissipated without complication and that there was no residual discomfort at the site of the injections.

At the cementation appointment, the patient reported thermal sensitivity. It was decided that a bilateral AMSA would again be administered as a means of pain control during the try-in and bonding phase of this appointment. One cartridge of lidocaine with 1:100,000 epinephrine was administered with 0.9 mL being delivered at each palatal landmark. The injection proceeded without incident and resulted in rapid and profound pulpal anesthesia. The porcelain veneers were temporarily placed on the teeth with water and evaluated in relationship to the lips in repose. Minor adjustments were required prior to bonding the veneers in place. Single Bond dental adhesive and clear Indirect Luting Cement (3M Dental), were used to adhere the veneers to the etched enamel surfaces. After photocuring, excess luting material was removed with a No. 12 scalpel blade (Bard Parker). Incisal refinements were made with a 104/065 fine diamond disk (Brasseler), and final polishing was done with silicone abrasive wheels (Dental Distributors). The patient was pleased with the esthetic and functional results of the finished restorations. Because the AMSA injections were utilized, no errors were made in the alignment of the veneer restorations with the lips, in spite of the fact that the patient was completely anesthetized during the preparation and cementation phases of treatment (Fig 8c).

Summary and conclusions

A newly introduced computer-controlled local anesthesia system provides dentists with a contemporary alternative to the traditional local anesthetic syringe. The computer drive and the disposable, ultralight handpiece enhances traditional injection techniques and makes new site-specific injections possible. The system controls the volume and pressure ratios of anesthetic solution, resulting in a precision flow rate. A drop of anesthetic solution precedes the needle even in tissues of resilience such as the palate, creating an anesthetic pathway for a virtually imperceptible injection without the use of topical anesthetic.

Because palatal injections can now be administered with operator ease and complete patient comfort, a new palatal-approach anterior, middle superior alveolar block injection has been described. Profound pulpal anesthesia of the maxillary central incisor through the second premolar and the palatal tissue in the region can be obtained from 0.6 to 0.9 mL of anesthetic solution without any numbness of the lips, face, or muscles of expression. The AMSA injection represents a practical and efficacious new concept for local anesthesia of maxillary teeth. Other site-specific local anesthetic injections may also be discovered using this computer-controlled technology.

References

1. Nevin M, Puterbaugh P. Conduction, Infiltration and General Anesthesia in Dentistry, ed 3. New York: Dental Items of Interest Publishing Co, 1927.
2. Friedman M, Hochman M. A 21st century computerized injection system for local pain control. *Compendium* 1987;18:995-1003.
3. Krochak M. Desensitization to fear of dental injections using a precision metered injection system. *Compendium* 1987;19:1-12.
4. Loetscher CA, Melton DC, Walton RE. Injection regimen for anesthesia of the maxillary first molar. *J Am Dent Assoc* 1988;117:337-340.
5. Archer WH. *A Manual of Dental Anesthesia*, ed 2. Philadelphia: Saunders, 1958.
6. Malamed SF, Trieger N. Intraoral maxillary nerve block: An anatomical and clinical study. *Anesth Prog* 1983;30:44-48.
7. Fischer G, Grossman L. *Local Anesthesia in Dentistry*, ed 4. Philadelphia: Lea & Febiger, 1933.
8. Kaufman E, Weinstein P, Milgrom P. Difficulties in achieving local anesthesia. *J Am Dent Assoc* 1984;108:205-208.
9. Nevin M. *Problems in Dental Local Anesthesia*, ed 2. New York: Dental Items of Interest Publishing Co, 1954.
10. Sicher J, DuBrul EL. *Oral Anatomy*, ed 6. St Louis: Mosby, 1975.
11. Smith GN, Pashley DH. Periodontal ligament injection: Evaluation of systemic effects. *Oral Surg Oral Med Oral Pathol* 1983;56:571-574.
12. Jastak JT, Yageila JA, Donaldson D. *Local Anesthesia of the Oral Cavity*. Philadelphia: Saunders, 1995.
13. Chiche G, Pinault A. *Esthetics of Anterior Fixed Prosthodontics*. Chicago: Quintessence, 1994.
14. Hochman M, Chiarello D, Hochman C, Lopatkin R, Pergola S. Computerized local anesthesia vs traditional syringe technique: Subjective pain response. *NY State Dent J* 1997;63(7):24-29.
15. Fischer G. *Die Lokale Anästhesie in der Zahnheilkunde*. Berlin: Verlag von Hermann Meuber, 1911.
16. Frazer M. Contributing factors and symptoms of stress in dental practice. *Br Dent J* 1992;173(3):111.
17. Hamburg HL. Preliminary study of patient reaction to needle gauge. *NY State Dent J* 1972;38:425-426.
18. Yaacob HE, Noor GM, Malek SN. The pharmacological effect of xylocaine topical anaesthetic: A comparison with a placebo. *Sing Dent J* 1981;6(2):55-57.
19. Holst A, Evers H. Experimental studies of new topical anaesthetics on the oral mucosa. *Swed Dent J* 1985;9(5):185-191.
20. Rosivack RG, Koenigsberg SR, Maxwell KC. An analysis of the effectiveness of two topical anesthetics. *Anesth Prog* 1990;37:290-292.
21. Tagger E, Tagger M, Sarnet H, Mass E. Periodontal ligament injection in the dog primary dentition: Spread of local anesthetic solution. *Int J Ped Dent* 1994;4(3):159-166.
22. Pashley EL, Nelson R, Pashley DH. Pressures created by dental injections. *J Dent Res* 1981;60:1742-1748.
23. Roberts DH, Sowray JH. *Local Analgesia in Dentistry*. Great Britain: Stonebridge Press, 1970.