Anesthetic Efficacy of the Anterior Middle Superior Alveolar (AMSA) Injection

Shelly Lee, DDS, MS,* Al Reader, DDS, MS,† John Nusstein, DDS, MS,† Mike Beck, DDS, MA,‡ and Joel Weaver, DDS, PhD§

*Private practice, Wapakoneta, Ohio; †Department of Endodontics, ‡Department of Oral Biology, and §Department of Oral and Maxillofacial Surgery, Oral Pathology, and Anesthesiology, The Ohio State University, Columbus, Ohio

The purpose of this prospective, randomized, blinded study was to determine the anesthetic efficacy of the anterior middle superior alveolar (AMSA) injection using the computer-assisted Wand Plus injection system versus a conventional syringe. The authors, using a crossover design, randomly administered in a blind manner 2 AMSA injections utilizing the computer-assisted injection system and a conventional syringe to 40 subjects during 2 separate appointments. A pulp tester was used to test for anesthesia, in 4-minute cycles for 60 minutes, of the central and lateral incisors, canine, and first and second premolars. Anesthesia was considered successful when 2 consecutive no responses (80 readings) with the pulp tester were obtained. For all teeth, except the central incisor, the use of the computer-assisted injection system was significantly ($P < .05$) more likely to result in pulpal anesthesia than the use of the conventional syringe technique. For the computer-assisted injection system, successful pulpal anesthesia ranged from 35 to 58%, and for the conventional syringe, successful pulpal anesthesia ranged from 20 to 42%. For both techniques, the onset of pulpal anesthesia was slow, and duration of pulpal anesthesia declined steadily over 60 minutes. We conclude that although the AMSA injection using the computer-assisted injection system was more successful than the conventional syringe technique, the rather modest to low success rates, slow onset, and declining duration of pulpal anesthesia over 60 minutes would not ensure predictable pulpal anesthesia from the second premolar to the central incisor.

Key Words: AMSA injection; Local anesthesia; Computer-assisted injection.

Traditionally, maxillary teeth have been anesthetized by administering an infiltration injection on the buccal or labial aspect of the target tooth. Recently, a new technique has been introduced for anesthetizing maxillary teeth—the anterior middle superior alveolar (AMSA) injection.[1–3] Friedman and Hochman[1–3] state that pulpal anesthesia of the maxillary central and lateral incisors, canines, and first and second premolars for an expected duration of 45–60 minutes will be achieved with the AMSA injection of 0.6 to 1.4 mL of anesthetic solution. The authors[1–3] also state that palatal soft tissue anesthesia is achieved without numbness to the lips and face or interference with the muscles of facial expression. A bilateral AMSA injection supposedly anesthetizes 10 maxillary teeth extending from the second premolar on 1 side to the second premolar on the opposite side.[2] The AMSA injection site is located palatally at a point that bisects the premolars and is approximately halfway between the midpalatine raphe and the crest of the free gingival margin (Figure 1).[1–3] The AMSA injection derives its name from the injection's ability to supposedly anesthetize both the anterior and middle superior alveolar (MSA) nerves.[1–3]

The MSA and anterior superior alveolar (ASA) nerves branch from the infraorbital nerve before they exit from the infraorbital foramen (Figure 2).[4] The MSA nerve is thought to innervate the maxillary premolars and plays

Received January 14, 2004; accepted for publication April 28, 2004.

Address correspondence to Prof Al Reader, Department of Endodontics, College of Dentistry, The Ohio State University, 305 W. 12th Avenue, Columbus, OH 43218; reader.2@osu.edu.

Anesth Prog 51:80–89 2004
© 2004 by the American Dental Society of Anesthesiology

ISSN 0003-3006/04/$9.50
SSDI 0003-3006(04)

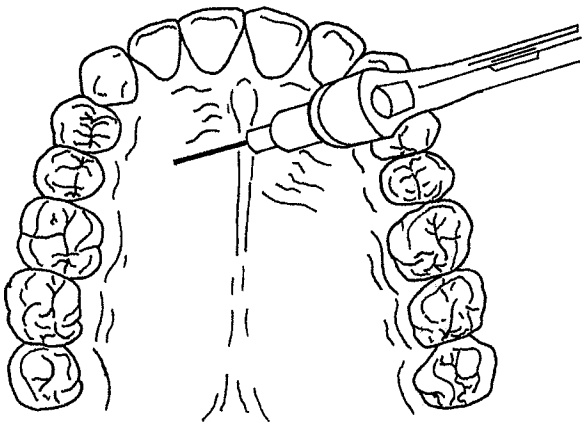

Figure 1. Palatal injection site for the anterior middle superior alveolar (AMSA) injection.

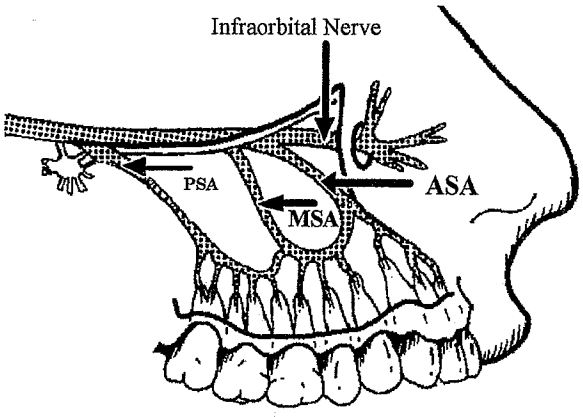

Figure 2. Distribution of the maxillary division of the trigeminal nerve showing the middle superior alveolar (MSA) nerve and anterior superior alveolar (ASA) nerve. The infraorbital and posterior superior alveolar (PSA) nerves are also identified.

some role in pulpal innervation of the mesiobuccal root of the first molar.[4] The ASA nerve provides pulpal innervation to the central and lateral incisors and canines.[4] The plexus where the 2 nerves join is the target site for the AMSA injection.[1–3]

Traditionally, palatal injections administered with a conventional syringe have the potential to be painful. The Wand Plus (Milestone Scientific, Deerfield, Ill) local anesthesia system has been developed to supposedly enable a virtually painless injection.[1–3,5] The majority of the literature on this computer-assisted injection system has addressed the pain of injection with the computer-assisted injection system compared with injections using a conventional syringe.[6–18] In general, the results have been favorable with the computer-assisted injection system,[6,7,11–18] with 2 studies showing no difference[8,9] and 1 study showing higher pain ratings[10] with the computer-assisted injection system.

Friedman and Hochman[1] state that the AMSA technique is comfortable for the patient. Historically, there are 8 studies[6,8–11,15,17,18] that have evaluated the pain of the AMSA or palatal injections. Except for the studies by Asarch et al,[8] Saloum et al,[9] and Goodell et al,[10] the computer-assisted injection system technique resulted in less pain than the conventional syringe injection for AMSA and palatal injections,[6,11,15,17] or the patients had low pain ratings with the computer-assisted injection system technique for the AMSA injection.[18]

Fukayama et al[18] evaluated the anesthetic efficacy (no response to 80 readings with the pulp tester) of the AMSA injection when administered with the Wand method. They concluded that it seems to be very effective for pulpal anesthesia of the lateral incisors, canines, and premolars. However, their graphs of the incidence of pulpal anesthesia generally showed slow onset of anesthesia, a rather short incidence of the maximum 80 readings, and a sharp decline of anesthesia. Therefore, the conclusion that pulpal anesthesia for the AMSA is very effective is questionable. Further studies are needed to determine the anesthetic efficacy of the AMSA injection.

The purpose of this prospective, randomized, blinded study was to determine the anesthetic efficacy of the AMSA injection using the computer-assisted Wand Plus injection system versus a conventional syringe.

MATERIALS AND METHODS

Forty adult subjects participated in this blinded study. All subjects were in good health and were not taking any medication that would alter pain perception as determined by a written health history and oral questioning. The Ohio State University Human Subjects Review Committee approved the study, and written informed consent was obtained from each subject.

The 40 subjects randomly received 2 AMSA injections at 2 separate appointments spaced at least 1 week apart in a crossover design. The 40 subjects received AMSA injections of 1.4 mL of 2% lidocaine (28 mg) with 1 : 100,000 epinephrine (14 μg) (Xylocaine; Dentsply, York, Penn) using the Wand Plus local anesthesia system at 1 appointment and the same amount of lidocaine with epinephrine, using a conventional syringe, at the other appointment. With the crossover design, there were 80 total injections administered, and each subject served as his or her own control. Forty AMSA injections were administered on the right side, and 40 AMSA injections were administered on the left side. The same side randomly chosen for the first injection was used again for the second injection. The senior author (S.L.) gave all injections. Additionally, the senior author (S.L.) practiced the AMSA injection on emer-

gency and routine endodontic patients using both the computer-assisted injection system and conventional syringe for 3 months before starting the current study.

The computer-assisted injection system[5] is a microprocessor-driven device that delivers a controlled infusion of anesthetic solution. The unit accepts standard 1.8-mL dental anesthetic glass cartridges. The microprocessor monitors and varies the infusion pressure while maintaining a constant flow rate. An electronically driven plunger contacts the rubber plunger in the cartridge and expels the anesthetic solution at a precisely regulated rate. Sterile tubing connects the cartridge receptor to a penlike, hand-held plastic wand that is attached to a Luer-Lok needle (Becton Dickinson and Co., Franklin Lakes, NJ), together forming a disposable syringe assembly. A small portion of solution from a standard cartridge is lost during the purge cycle, and some of the solution remains in the cartridge and tubing; thus only 1.4 mL of anesthetic solution from a standard cartridge is delivered. Flow rate, initiation and cessation of flow, and aspiration are controlled with a foot pedal. To prevent cross-contamination, the handpiece, microtubing, and anesthetic cartridge are designed for single use only.

The test teeth were the maxillary central incisor, lateral incisor, canine, and first and second premolars. The mandibular canine was used as the unanesthetized control to ensure that the pulp tester was operating properly and that the subject was responding appropriately during the experiment. Clinical examinations indicated that all teeth were free of caries, large restorations, and periodontal disease, and that none had a history of trauma or sensitivity.

At the beginning of each appointment and before any injections were given, the experimental teeth and control canine were tested 3 times by means of a Kerr pulp tester (Analytic Technology Corp, Redmond, Wash) to record baseline vitality. After isolation with cotton rolls and drying with gauze, toothpaste was applied to the probe tip, which was placed midway between the gingival margin and the incisal or occlusal edge of the tooth to be tested. The current rate was set on the pulp tester at 25 seconds to increase from no output (0) to the maximum output (80). The number at initial sensation was recorded. Trained research personnel who were blinded to the injection techniques administered performed all preinjection and postinjection tests.

Before the experiment, the 2 techniques of anesthetic administration were randomly assigned 6-digit numbers from a random number table. The random numbers were assigned to a subject to designate which technique was to be administered at each appointment. The blinding of the AMSA injection was accomplished by (a) blindfolding the subject during the administration of the injections at both appointments; and (b) during the conventional syringe injection, the computer-assisted injection system was activated so the subject would hear the chiming of the unit at both appointments. The handpiece of the computer-assisted injection system was placed into a suction tip to collect the anesthetic solution while the conventional syringe injection was given. The suction tip was also activated during the computer-assisted injection so the subject would not perceive a difference between injection techniques due to the use of the suction tip. Additionally, during the computer-assisted injection, a conventional loaded syringe was placed on the instrument tray so the subject would see both the computer-assisted injection system and conventional syringe as he or she entered the operatory. Only the random numbers were recorded on the data collection sheets to further blind the experiment.

For the conventional syringe injection, 0.4 mL of anesthetic solution was withdrawn from a standard cartridge of 2% lidocaine with 1 : 100,000 epinephrine using a 1-mL tuberculin syringe (Becton Dickinson and Co, Franklin Lakes, NJ) and a sterile technique. This cartridge was placed in a conventional aspirating syringe (Dentsply, York, Penn) equipped with a 27-gauge 1-inch needle (Sherwood Medical, St. Louis, Mo). Therefore, this procedure ensured that the same volume of anesthetic solution was delivered with each of the 2 techniques.

For the computer-assisted injection system, a cartridge of 2% lidocaine with 1 : 100,000 epinephrine was placed into the plastic barrel of the unit's handpiece assembly and then placed into the cartridge holder socket with a quarter turn in a counterclockwise direction. The cap was removed from the needle and the foot pedal depressed once to activate the purge cycle to remove air from the plastic tubing and fill the line with anesthetic solution.

The AMSA injection was administered with the computer-assisted injection system according to the recommendations of Friedman and Hochman.[1–3] The subjects were informed that the injection would take almost 5 minutes and that they would hear chimes during the injection. Subjects were placed in a supine position with the head tilted up and back. The AMSA injection site was centered halfway between the midpalatine raphe and the gingival margin of the first and second premolars (Figure 1). A cotton-tip applicator was used to apply 0.2 mL of topical anesthetic (benzocaine; Patterson Brand, St. Paul, Minn) at the injection site for 1 minute. The injection was performed with a 27-gauge, 1-inch Luer-Lok needle. For the needle insertion phase of the injection, the needle bevel was placed against the palatal tissue without puncturing the tissue, and a plain cotton-tip applicator was firmly pressed on the needle tip for

Table 1. Percent of Anesthetic Success (2 Consecutive No Responses at the 80 Reading) of the Anterior Middle Superior Alveolar (AMSA) Injection

Tooth	*Computer-assisted Injection System*	*Conventional Syringe*
Second premolar	55% (22/40)	42% (17/40)
First premolar	42% (17/40)	20% (8/40)
Canine	52% (21/40)	32% (13/40)
Lateral incisor	58% (23/40)	42% (17/40)
Central incisor	35% (14/40)	30% (12/40)

premolars. At 2 minutes, the canine was tested. At 3 minutes, the lateral and central incisors were tested. At 4 minutes, the mandibular control canine was tested. The testing continued in 4-minute cycles for a period of 60 minutes.

No response from the subject to the maximum output (no response at the 80 reading) of the pulp tester was used as the criterion for pulpal anesthesia. Anesthesia was considered successful when 2 consecutive no responses at the 80 readings were obtained. Anesthetic success only considers when 2 consecutive 80 readings occur at some point over the 60 minutes.

Data were analyzed statistically. A comparison of anesthetic success between the 2 AMSA techniques was made for each experimental tooth using a logistic regression model with age, gender, time period, and anesthetic technique as the predictor variables. Logistic regression considers the odds of a tooth having pulpal anesthesia (no response at the 80 readings) across all time periods (total time from the start of the experiment through 60 minutes) when the potential confounders of subject, age, and gender are controlled. Simply put, this technique allows the clinician to appreciate how much more likely a tooth is to become anesthetized (the odds) when 1 technique is compared with another with all factors being equal. Comparisons were considered significant at $P < .05$.

RESULTS

Forty adult subjects, 20 women and 20 men with an average age of 27 years (range, 19–36 years) participated.

Anesthetic success of the AMSA injection is presented in Table 1. For the Wand Plus technique, successful pulpal anesthesia ranged from 35 to 58% from the second premolar to the central incisor. Using the conventional syringe technique, successful pulpal anesthesia ranged from 20 to 42%. For all teeth, except the central incisor, the use of the computer-assisted injection system was significantly ($P < .05$) more likely to result in pulpal anesthesia than the use of the conventional syringe technique (Table 2).

Table 2. Logistic Regression Analysis to Determine the Effect the Anesthetic Technique Had on Each Tooth's Odds of Achieving Pulpal Anesthesia (No Response at the 80 Reading Over 60 Minutes)

Tooth	*Odds Ratio**	*LCB (95%)*	*UCB (95%)*	*P value*
Second premolar	1.70	1.06	2.71	.0027
First premolar	2.68	1.78	4.05	<.0001
Canine	2.57	1.57	4.21	.0002
Lateral incisor	1.65	1.03	2.66	.0382
Central incisor	1.59	0.91	2.79	.1031

* Adjusted odds ratios for pulpal anesthesia utilizing the computer-assisted injection system and compared with the conventional syringe are presented. The odds ratios were adjusted for age, gender, and time period. LCB indicates lower confidence boundary; UCB, upper confidence boundary.

Statistical analysis of onset and duration, between the anesthetic techniques, was not performed because of the low number of successes with the conventional syringe technique resulting in insufficient numbers for matched-pairs analysis. Figures 3–7 show the incidence of pulpal anesthesia for the individual teeth.

DISCUSSION

The use of no response to the 80 readings (maximum output of the pulp tester) as a criterion for pulpal anesthesia was based on the clinical studies of Dreven et al[19] and Certosimo and Archer.[20] These studies[19,20] showed that no response at the 80 reading ensured pulpal anesthesia in vital asymptomatic teeth. Additionally, Certosimo and Archer[20] demonstrated that electric pulp testing readings less than 80 resulted in pain during restorative procedures.

Clinically, the results of this study would indicate that the conventional syringe technique would generally be less effective than the Wand Plus technique in the AMSA injection (Tables 1 and 2; Figures 3–7). However, the computer-assisted injection technique resulted in successful pulpal anesthesia (2 consecutive 80 readings) from 35 to 58% of the time and would not clinically ensure predictable pulpal anesthesia from the second premolar to the central incisor. The use of the AMSA injection for clinical anesthesia of these 5 teeth would be theoretically advantageous because only 1 injection would unilaterally anesthetize all these teeth for 60 minutes, with no collateral anesthesia to the lips and muscles of facial expression; thus it would be ideal for restorative and cosmetic dentistry.[1–3] Unfortunately, we could not confirm the clinical impressions that the

the prepuncture phase of needle insertion.[1–3,5] The computer-assisted injection system was activated at a slow rate (by partially depressing the foot pedal) for 8 seconds to supposedly force the anesthetic solution into the tissue.[5] By removing the foot from the foot pedal, the computer-assisted injection system unit was activated on cruise control (continuous flow of anesthetic solution at the slow rate). One chime from the computer-assisted injection system machine corresponded to 1 second, allowing audible monitoring of the elapsed time. Approximately 1 drop of anesthetic solution was delivered every other second on the slow setting. The handpiece, with attached needle, was reoriented to a 45° angle and rotated in an axial manner (45° clockwise and 45° counterclockwise) for needle insertion. The needle was slowly advanced 1–2 mm, followed by a brief pause of 4 chimes. The needle was advanced another 2–4 mm until bone was gently contacted, followed by a pause of 4 chimes. The needle was then withdrawn slightly. The cotton-tip applicator was then removed to observe the palate for blanching. Approximately 0.08 mL of anesthetic solution was delivered during the needle insertion phase.

For the solution deposition phase of the injection, the computer-assisted injection system's handpiece was held in position at the depth described above, and the computer-assisted injection system continued on cruise control, at the slow setting, to deposit the anesthetic solution. Visually monitoring the green lights on the unit and audibly monitoring the corresponding chimes determined when the deposition of solution was complete. Approximately 1.32 mL of anesthetic solution was delivered during the solution deposition phase. The author had direct vision of the injection site, and if leakage of the anesthetic solution was noticed, the needle was repositioned until no leakage occurred. The author waited 10 seconds before slowly removing the needle from the injection site. This supposedly allowed the anesthetic solution to dissipate within the tissue and reduced the amount of solution dripping from the site before needle withdrawal. After needle withdrawal, the conventional syringe was emptied into the sink and placed back on the instrument tray so both the computer-assisted injection system and the syringe appeared used. The blindfold was then removed.

For the conventional syringe injection, the subject was informed that the injection would take almost 5 minutes and that they would hear chimes during the injection. The subject was placed in a supine position with the head tilted up and back. The same AMSA injection site was chosen as for the computer-assisted injection system technique (Figure 1). A cotton-tip applicator was used to apply 0.2 mL of topical anesthetic (benzocaine, Patterson Brand) at the injection site for 1 minute. The injection was performed with a 27-gauge 1-inch needle (Sherwood Medical). For the needle insertion phase of the injection, the needle bevel was placed against the palatal tissue, without puncturing the tissue, and a plain cotton-tip applicator was firmly pressed on the needle tip for the prepuncture phase of needle insertion.[1–3,5] The plunger on the conventional syringe was slowly depressed to supposedly force the anesthetic solution into the tissue.[5] During this time, the computer-assisted injection system was activated by means of the foot control to activate the chiming and allow audible monitoring of the elapsed time of the conventional syringe injection. The conventional syringe needle was reoriented to a 45° angle and rotated slightly for needle insertion. The plunger was slowly depressed and the needle was advanced 1–2 mm. The needle was advanced another 2–4 mm, while further depressing the syringe handle, until bone was gently contacted. The needle was then withdrawn slightly. The cotton-tip applicator was then removed to observe the palate for blanching. Although the amount of local anesthetic delivered with the computer-assisted injection system can be approximated, it is not known the exact volume delivered with the conventional syringe during the needle insertion phase. We tried to mimic the amount given by the computer-assisted injection system (approximately 0.08 mL of anesthetic solution).

For the solution deposition phase of the injection, the conventional syringe was held in position at the depth described above, and anesthetic solution was slowly deposited. Visually monitoring the green lights on the computer-assisted injection system's unit, observing the rubber stopper within the anesthetic cartridge, and audibly monitoring the corresponding chimes determined the rate of solution deposition. Approximately 1.32 mL of anesthetic solution was delivered during the solution deposition phase because the amount remaining in the syringe, after the needle insertion phase, was $1.4 - 0.08 = 1.32$ mL. As with the computer-assisted injection, the author had direct vision of the injection site, and if leakage of the anesthetic solution was noticed, the needle was repositioned until no leakage occurred. Likewise, the author waited 10 seconds before slowly removing the needle from the injection site to reduce the potential for the anesthetic solution dripping from the injection site after needle removal. After needle withdrawal, the conventional syringe was placed back on the instrument tray, and the computer-assisted injection system's handpiece was withdrawn from the suction apparatus and placed into its plastic housing to mimic its use. The blindfold was then removed.

The depth of anesthesia was monitored with the electric pulp tester. At 1 minute after the AMSA injection, pulp test readings were obtained for the first and second

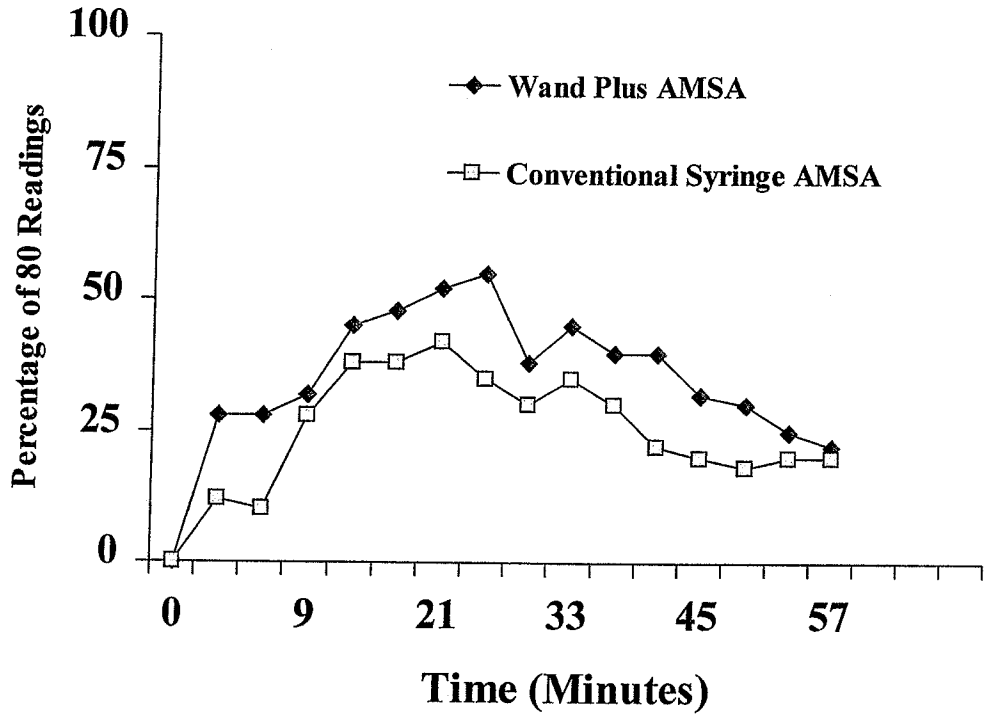

Figure 3. Incidence of second premolar pulpal anesthesia as determined by lack of response to electrical pulp testing at the maximum setting (percentage of 80 readings) at each postinjection time interval for the 2 injection techniques.

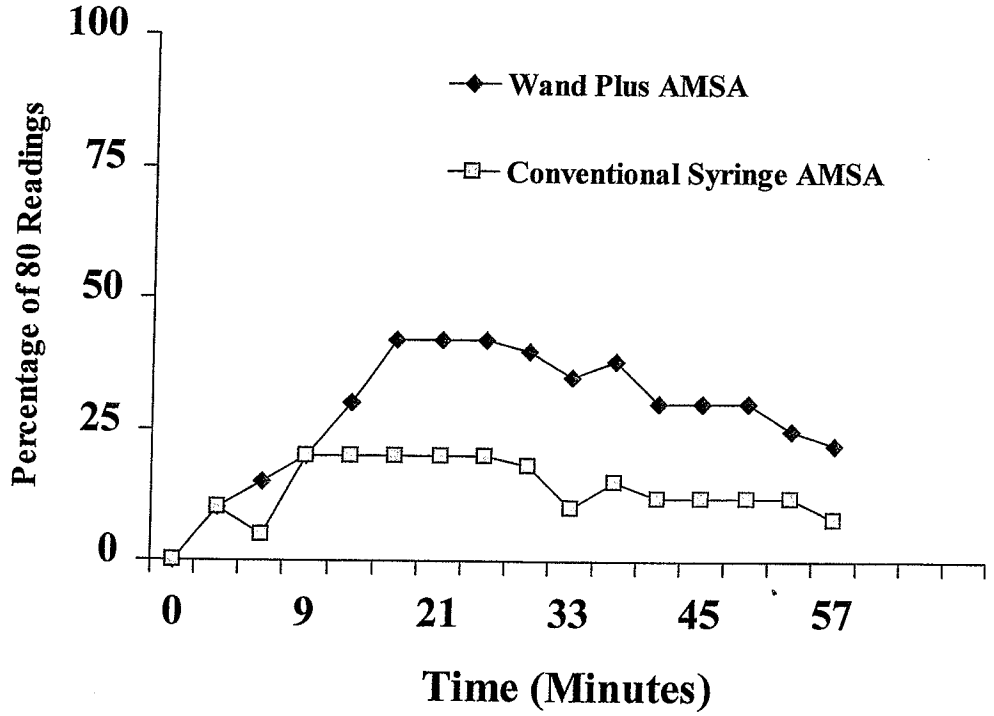

Figure 4. Incidence of first premolar pulpal anesthesia as determined by lack of response to electrical pulp testing at the maximum setting (percentage of 80 readings) at each postinjection time interval for the 2 injection techniques.

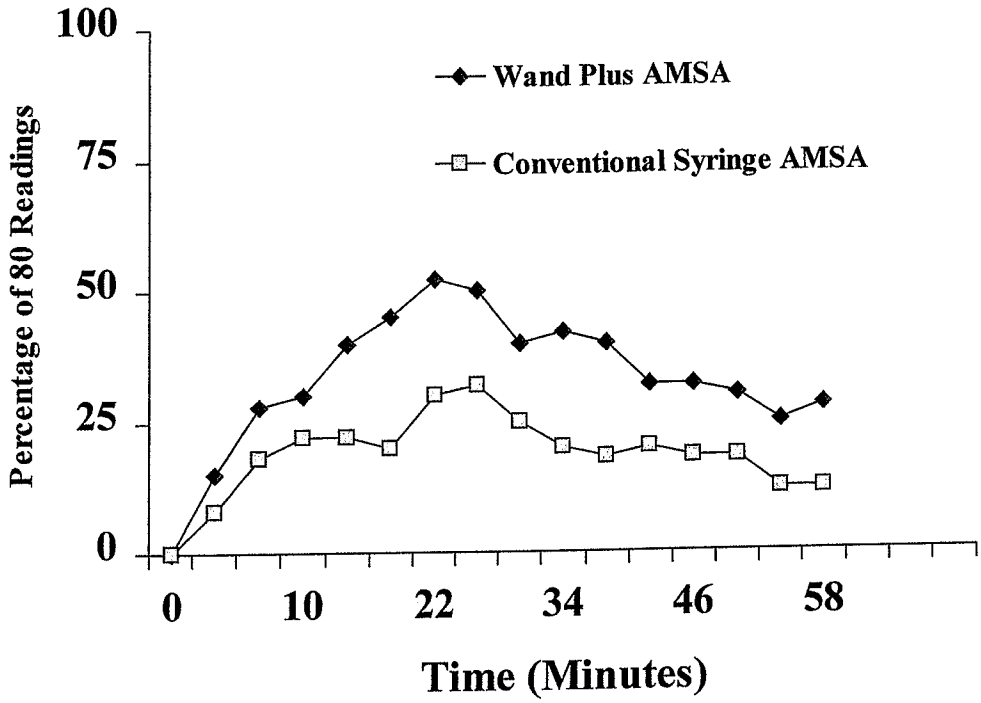

Figure 5. Incidence of canine incisor pulpal anesthesia as determined by lack of response to electrical pulp testing at the maximum setting (percentage of 80 readings) at each postinjection time interval for the 2 injection techniques.

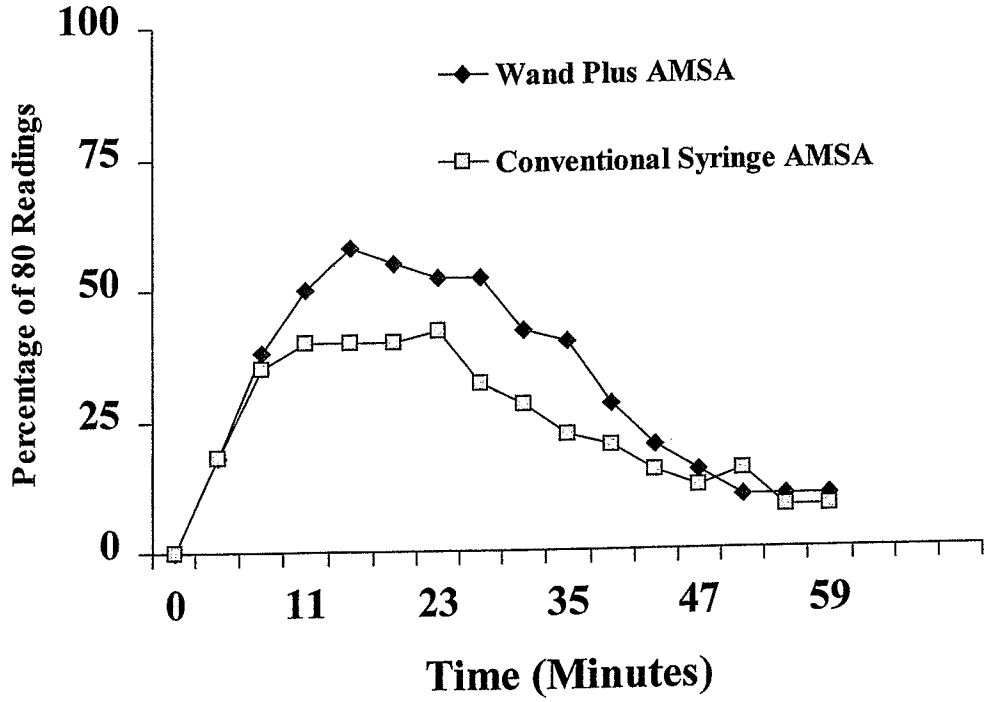

Figure 6. Incidence of lateral incisor pulpal anesthesia as determined by lack of response to electrical pulp testing at the maximum setting (percentage of 80 readings) at each postinjection time interval for the 2 injection techniques.

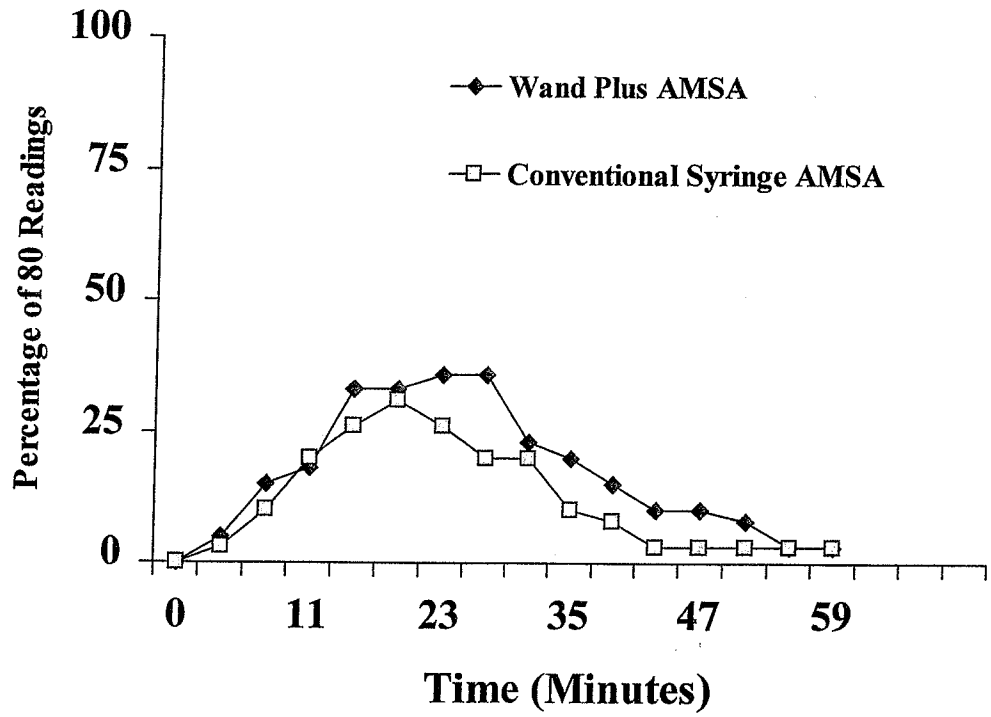

Figure 7. Incidence of central incisor pulpal anesthesia as determined by lack of response to electrical pulp testing at the maximum setting (percentage of 80 readings) at each postinjection time interval for the 2 injection techniques.

AMSA injection would be so successful. The shape of the palatal vault was not recorded in this study. However, in retrospect we feel we had a fairly normal distribution of shallow and deep vaults in this study. The effect of a deep or shallow palatal vault on the success of the AMSA injection could be examined. Because we studied a young adult population, the results of this study may not apply to children or the elderly.

In general, the pattern of pulpal anesthesia for all teeth showed that anesthesia, regardless of technique, had a gradual onset of pulpal anesthesia, with the highest percentage of anesthesia occurring at 9 to 26 minutes (Figures 3–7). The gradual onset of pulpal anesthesia is most likely due to the time it takes for the anesthetic solution to pass through the palatine process. In the current study and for both injection techniques, we observed palatal blanching extending anteriorly to the incisive papilla and posteriorly to include the soft palate. The palatal blanching did not cross the midpalatine raphe. Therefore, it seems likely that some portion of the anesthetic solution remains in the palatal soft tissue and the remainder passes through the palatine process to anesthetize the maxillary teeth.

The duration of pulpal anesthesia gradually declined over the 60 minutes (Figures 3–7). Therefore, we could not confirm the clinical impression[1–3] that duration of pulpal anesthesia with the AMSA injection was 60 minutes.

Fukayama et al[18] stated that the AMSA injection, administered with the computer-assisted injection technique, seems to be very effective for pulpal anesthesia of the lateral incisors, canines, and premolars. Although they did not report success rates (no response at 80 readings) for the individual teeth, their graphs revealed the following approximate results for anesthetic success: 72% for the second premolar, 65% for the first premolar, 86% for the canine, 65% for the lateral incisor, and 42% for the central incisor. Although these results may seem somewhat acceptable, these readings were the highest values recorded and were only sustained for approximately 10 minutes. Additionally, these highest readings occurred from 20 to 40 minutes into the appointment—indicating slow onset. Duration of pulpal anesthesia declined at approximately 30 to 50 minutes. Generally, the results of the Fukayama et al[18] study were similar to the pattern of pulpal anesthesia we recorded in this study, except that they showed a higher incidence of pulpal anesthesia. The difference between the Fukayama et al[18] study and our results may be related to the higher number of subjects in our study or differences in subject populations. Regardless of the differences, both studies showed a slow onset, a rather short incidence of the maximum 80 readings, and a sharp decline of anesthesia. Clinically, these are not the qualities of effective pulpal anesthesia.

It seems the slow onset, moderate to low success rates

(Table 1), and gradual decline in pulpal anesthesia (Figures 3–7) for the AMSA injection is largely dictated by the pattern of diffusion of the anesthetic solution across the palatine process. Although the AMSA injection has been called a nerve block, it did not behave like a nerve block. Malamed[4] defines a nerve block as when a local anesthetic solution is deposited close to a main nerve trunk. Therefore, the anesthetic solution would have to be deposited close to the ASA and MSA nerves. The result would be a high rate of pulpal anesthesia from the second premolar to the central incisor without a pronounced decline of pulpal anesthesia over the 60 minutes. Perhaps a factor in the success of the AMSA injection would be the presence or absence of the MSA nerve. Various cadaver dissection studies[21–25] have found the presence of the MSA nerve in 30 to 72% of the specimens. When absent, the ASA nerve usually supplies innervation to the premolars.[22] Exactly what role the absence of the MSA nerve plays in the success of the AMSA is not known. Premdas and Pitt Ford[26] demonstrated that pulpal anesthesia of the first premolar was possible with a palatal, conventional syringe injection of 1 mL of 2% lignocaine with 1 : 80,000 epinephrine. However, due to the small number of subjects and the use of a higher concentration of epinephrine, it is difficult to compare the results of Premdas and Pitt Ford[26] with the current study. We can conclude that the AMSA injection, as administered in this study, did not effectively block the ASA and MSA nerves, nor was the anesthetic solution in close enough proximity to the apices of all 5 teeth to provide complete pulpal anesthesia.

The lower success rate of the conventional syringe technique (Tables 1 and 2) may be due to the superiority of the computer-assisted injection system to deliver the anesthetic solution at a controlled, continuous flow rate. With the conventional syringe technique, flow rate and fluid pressure are operator-dependent and cannot be precisely controlled. Although every effort was made to manually administer the AMSA injection consistent with the computer-assisted injection system, this was not possible due to inability to control the flow rate as precisely as the computer-assisted injection system. Therefore, we can speculate that a controlled delivery of anesthetic solution with the computer-assisted injection system perhaps created an improved pressure gradient environment for the diffusion of solution through the palatine process. Further studies are needed to resolve this question.

We conclude that although the AMSA injection using the Wand Plus was more successful than the conventional syringe technique, the rather modest to low success rates, slow onset, and declining duration of pulpal anesthesia over 60 minutes would not ensure predictable pulpal anesthesia from the second premolar to the central incisor.

ACKNOWLEDGMENTS

This study was supported by Graduate Endodontic Research Funds and The Steven Goldberg Memorial Fund.

REFERENCES

1. Friedman M, Hochman M. A 21st century computerized injection system for local pain control. *Compendium.* 1997;18:995–1003.

2. Friedman M, Hochman M. The AMSA injection: a new concept for local anesthesia of maxillary teeth using a computer-controlled injection system. *Quintessence Int.* 1998;29: 297–303.

3. Friedman M, Hochman M. Using AMSA and P-ASA nerve blocks for esthetic restorative dentistry. *Gen Dent.* 2001;5:506–511.

4. Malamed SF. *Handbook of Local Anesthesia.* 4th ed. St. Louis, Mo: Mosby; 1997.

5. *Wand Plus Computer Controlled Anesthetic Delivery System, 2000, Product Information Guide.* Deerfield, Ill: Milestone Scientific, Dental Division; 2000.

6. Hochman M, Chiarello D, Bozzi-Hochman C, Lopatkin R, Pergola S. Computerized local anesthetic delivery vs. traditional syringe technique. *NY State Dent J.* 1997;63:24–29.

7. Levato C. Giving the Wand a shot. *Dent Pract Fin.* 1998;4:53–57.

8. Asarch T, Allen K, Petersen B, Beiraghi S. Efficacy of a computerized local anesthesia device in pediatric dentistry. *Pediatr Dent.* 1999;21:421–424.

9. Saloum FS, Baumgartner JC, Marshall G, Tinkle J. A clinical comparison of pain perception to the Wand and a traditional syringe. *Oral Surg Oral Med Oral Pathol Oral Radiol Endod.* 2000;86:691–695.

10. Goodell GG, Gallagher FJ, Nicoll BK. Comparison of a controlled injection pressure system with a conventional technique. *Oral Surg Oral Med Oral Pathol Oral Radiol Endod.* 2000;90:88–94.

11. Gibson RS, Allen K, Hutfless S, Beiraghi S. The Wand vs. traditional injection: a comparison of pain related behaviors. *Pediatr Dent.* 2000;22:458–462.

12. Nicholson JW, Berry TG, Summitt JB, Yuan CH, Witten TM. Pain perception and utility: a comparison of the syringe and computerized local injection techniques. *Gen Dent.* 2001;49:167–173.

13. Tan PY, Vukasin P, Chin ID, et al. The Wand local anesthetic delivery system. A more pleasant experience for anal anesthesia. *Dis Colon Rectum.* 2001;44:686–689.

14. Rosenberg ES. A computer-controlled anesthetic delivery system in a periodontal practice: patient satisfaction and acceptance. *J Esthetic Restor Dent.* 2002;14:39–46.

15. Primosch RE, Brooks R. Influence of anesthetic flow

rate delivered by the Wand local anesthetic system on pain response to palatal injections. *Am J Dent.* 2002;15:15–20.

16. True RH, Elliott R. Microprocessor-controlled local anesthesia versus the conventional syringe technique in hair transplantation. *Dermatol Surg.* 2002;28:463–468.

17. Allen KD, Kotil D, Larzelere RE, Hutfless S, Beiraghi S. Comparison of a computerized anesthesia device with a traditional syringe in preschool children. *Pediatr Dent.* 2002; 24:315–320.

18. Fukayama H, Yoshikawa F, Kohase H, Umino M, Suzuki N. Efficacy of anterior and middle superior alveolar (AMSA) anesthesia using a new injection system: The Wand. *Quintessence Int.* 2003;34:537–541.

19. Dreven L, Reader A, Beck M, Meyers W, Weaver J. An evaluation of the electric pulp tester as a measure of analgesia in human vital teeth. *J Endod.* 1987;13:233–238.

20. Certosimo A, Archer R. A clinical evaluation of the electric pulp tester as an indicator of local anesthesia. *Oper Dent.* 1996;21:25–30.

21. Olsen NH, Teuscher GW, Vehe KL. A study of the nerve supply to the upper anterior teeth. *J Dent Res.* 1955; 34:413–420.

22. McDaniel WL. Variations in nerve distributions of the maxillary teeth. *J Dent Res.* 1956;35:916–921.

23. Fitzgerald MJT, Scott JH. Observations on the anatomy of the superior dental nerves. *Brit Dent J.* 1958;104:205–208.

24. Heasman PA. Clinical anatomy of the superior alveolar nerves. *Brit J Oral Maxillofac Surg.* 1984;22:439–447.

25. Loetscher CA, Walton RE. Patterns of innervation of the maxillary first molar: a dissection study. *Oral Surg Oral Med Oral Pathol.* 1988;65:86–90.

26. Premdas CE, Pitt Ford TR. Effect of palatal injections on pulpal blood flow in premolars. *Endod Dent Traumatol.* 1995;11:274–278.